

**International Council of Ophthalmology**  
**International Ophthalmology Examinations**

**Clinical Sciences Sample Questions**

**Numbers of questions in each group**

<b>Clinical Sciences</b>	<b>Number of Questions</b>
i) General Medicine related to Ophthalmology	20
ii) Community Medicine & Public Health	8
iii) Ophthalmic pathology and Ocular tumours	12
iv) Neuro-ophthalmology	20
v) Paediatric Ophthalmology & Strabismus	20
vi) Orbit, eyelids and lacrimal disease	20
vii) Trauma, External disease and cornea	20
viii) Ocular inflammation and uveitis	20
ix) Glaucoma	20
x) Lens and cataract	20
xi) Retina and vitreous	20

**Question Formats**

**The formats vary, here are some examples. It is VITAL to read the questions very carefully. Be especially careful with negative questions- those with Not, Least etc (see 3 below)**

**1. Pathology & Microbiology**

**In microbial keratitis which of the following is most likely to be true?**

- a. Perforation is common in *Pseudomonas* keratitis.
- b. Bacterial and fungal keratitis are clinically distinct.
- c. Fungal keratitis is more common than bacterial keratitis in temperate climates.
- d. *Acanthamoeba* keratitis typically occurs in people who swim in public pools.

**2.**

**Paediatric Ophthalmology & Strabismus**

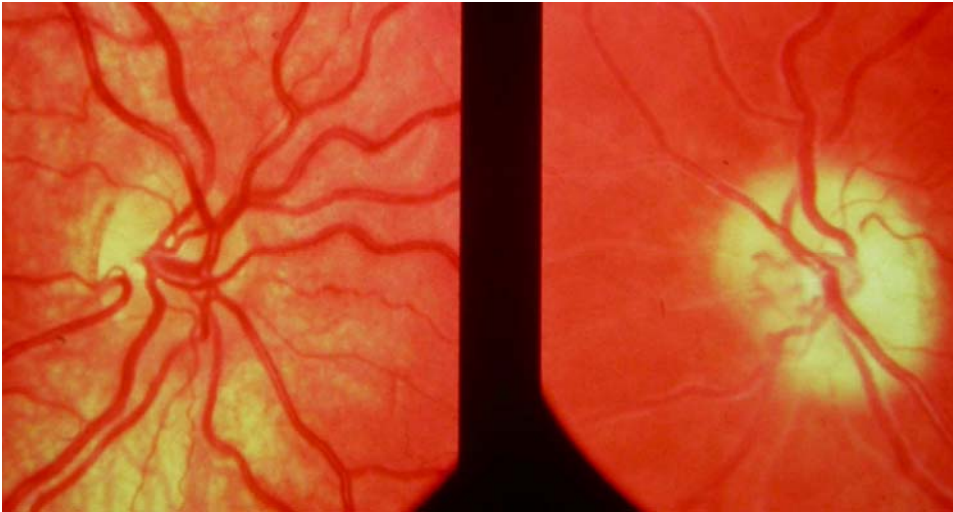**A 9-year-old child is admitted for surgery for a penetrating eye injury. His maternal grandmother died under anaesthesia 20 years previously; his mother has never had an anaesthetic. How would an anaesthetist (anaesthesiologist) best advise the family?**

- a. To proceed with the normal anaesthetic immediately avoiding the use of Suxamethonium (succinylcholine, Scoline).
- b. To have a muscle biopsy under local anaesthetic.
- c. To proceed, avoiding Halothane and having Dantrolene (Dantrolen, Dantrium) available.
- d. To send blood for urgent mutation analysis.

**3.**  
**'NEGATIVE' QUESTION**  
**Lens and Cataract**

**During a difficult cataract operation, the posterior capsule ruptures and the cataract completely dislocates into the posterior vitreous. Which of the following would be the LEAST safe next action?**

- a. Sulcus fixation of an intraocular lens, if the anterior capsule is intact.
- b. Retrieval of the dislocated lens.
- c. Suturing of the corneal wound.
- d. Anterior vitrectomy.



**Figure 4**

**4.**  
**Neuro-Ophthalmology**

**In Figure 4 (Above), the 18 year old patient with Neurofibromatosis type1 (NF1) has been blind in the left eye for 3 years and the right eye has a temporal hemianopia with a visual acuity of Log MAR 0.1 (6/6, 20/20, 1.0). Which of these statements is most likely to be correct about the diagnosis?**

- a. There is a bilateral optic nerve glioma.
- b. There is a right optic nerve glioma and a left optic nerve meningioma.
- c. There is a glioma involving the right side of the optic tract, chiasm and optic Nerve.
- d. The patient has had radiotherapy for a chiasmatic glioma

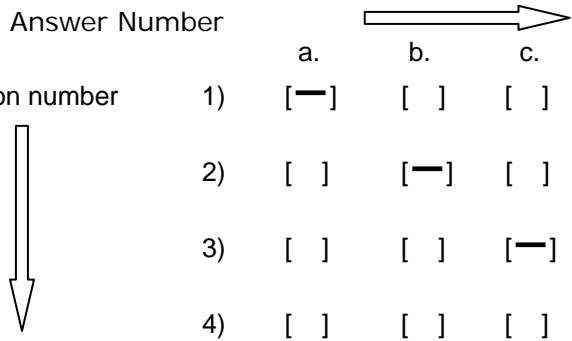
**5.**  
**Community Medicine & Public Health.**

**VISION 2020: The Right to Sight. Which of the following statements is CORRECT?**

- a. A successful VISION 2020 strategy would prevent some 500 million people becoming blind by 2020.
- b. The 5 major causes of avoidable blindness include Refractive Error.
- c. Men face a greater risk of vision loss than women.
- d. World Sight Day is observed on the second Thursday of March each year.

**On the answer sheet you have to put a BOLD HORIZONTAL line against the letter which you think correctly answers the question, thus:-**

	Answer Number				
		a.	b.	c.	d
Question number	1)	[—]	[ ]	[ ]	[ ]
	2)	[ ]	[—]	[ ]	[ ]
	3)	[ ]	[ ]	[—]	[ ]
	4)	[ ]	[ ]	[ ]	[—]



NB. These are not necessarily the correct answers to the above questions

**Do not forget to mark your answers clearly with a HORIZONTAL line:-[—].  
Oblique [/], even slightly oblique, or faint [-] lines will not be marked.**

**You do not HAVE to answer all the questions to pass the examination. Obviously, however, it helps!**

**There are no "trick" questions. If you do not understand the question you may ask the invigilator who may (but cannot guarantee to) be able to help you.**